

## STATE-OF-THE-ART REVIEW

# Drug-Coated Balloons for Coronary Artery Disease

## Third Report of the International DCB Consensus Group

Raban V. Jeger, MD,<sup>a</sup> Simon Eccleshall, MD,<sup>b</sup> Wan Azman Wan Ahmad, MD,<sup>c</sup> Junbo Ge, MD,<sup>d</sup> Tudor C. Poerner, MD,<sup>e</sup> Eun-Seok Shin, MD,<sup>f</sup> Fernando Alfonso, MD,<sup>g</sup> Azeem Latib, MD,<sup>h</sup> Paul J. Ong, MD,<sup>i</sup> Tuomas T. Rissanen, MD,<sup>j</sup> Jorge Saucedo, MD,<sup>k</sup> Bruno Scheller, MD,<sup>l</sup> Franz X. Kleber, MD,<sup>m</sup> for the International DCB Consensus Group

## ABSTRACT

Although drug-eluting stents are still the default interventional treatment of coronary artery disease, drug-coated balloons (DCBs) represent a novel alternative therapeutic strategy in certain anatomic conditions. The effect of DCBs is based on the fast and homogenous transfer of antiproliferative drugs into the vessel wall during single balloon inflation by means of a lipophilic matrix without the use of permanent implants. Although their use is established for in-stent restenosis of both bare-metal and drug-eluting stents, recent randomized clinical data demonstrate a good efficacy and safety profile in de novo small-vessel disease and high bleeding risk. In addition, there are other emerging indications (e.g., bifurcation lesions, large-vessel disease, diabetes mellitus, acute coronary syndromes). Because the interaction among the different delivery balloon designs, doses, formulations, and release kinetics of the drugs used is important, there seems to be no "class effect" of DCBs. On the basis of the amount of recently published data, the International DCB Consensus Group provides this update of previous recommendations summarizing the historical background, technical considerations such as choice of device and implantation technique, possible indications, and future perspectives.

(*J Am Coll Cardiol Intv* 2020;■:■-■) © 2020 The Authors. Published by Elsevier on behalf of the American College of Cardiology Foundation. This is an open access article under the CC BY-NC-ND license (<http://creativecommons.org/licenses/by-nc-nd/4.0/>).

**D**rug-coated balloons (DCBs) are a novel treatment strategy for coronary artery disease based on the fast and homogenous transfer of antiproliferative drugs into the vessel wall during single balloon inflation by means of a lipophilic matrix without the use of permanent implants (**Figure 1**). DCB-only percutaneous coronary intervention (PCI) is the concept of treating coronary

From the <sup>a</sup>University Hospital Basel, University of Basel, Basel, Switzerland; <sup>b</sup>Norfolk and Norwich University Hospital, Norwich, United Kingdom; <sup>c</sup>University Malaya Medical Centre, Kuala Lumpur, Malaysia; <sup>d</sup>Zhongshan Hospital, Fudan University, Shanghai, China; <sup>e</sup>Marienhospital, Aachen, Germany; <sup>f</sup>Ulsan Medical Center, Ulsan Hospital, Ulsan, South Korea; <sup>g</sup>Hospital Universitario de La Princesa, Madrid, Spain; <sup>h</sup>Montefiore Medical Center, New York, New York; <sup>i</sup>Tan Tock Seng Hospital, Singapore, Singapore; <sup>j</sup>Central Hospital of North Karelia, Joensuu, Finland; <sup>k</sup>Medical College of Wisconsin, Milwaukee, Wisconsin; <sup>l</sup>University Hospital Saarland, Homburg, Germany; and <sup>m</sup>Paul Gerhardt Stift, Wittenberg, Germany. Dr. Jeger has received research grants from B. Braun; and has received lecture honoraria from B. Braun, Nipro, and Cardionovum. Dr. Eccleshall has received research grants and lecture honoraria from B. Braun; and has received lecture honoraria from Boston Scientific. Dr. Ong has received research grants from Medtronic and Biosensors. Dr. Rissanen has received research grants and lecture honoraria from B. Braun and Boston Scientific. Dr. Saucedo is a consultant for B. Braun. Dr. Scheller is a shareholder in InnoRa; and is named as a coinventor on patent applications submitted by Charité University Hospital (Berlin, Germany). Dr. Kleber has received lecture honoraria from B. Braun. All other authors have reported that they have no relationships relevant to the contents of this paper to disclose. The authors attest they are in compliance with human studies committees and animal welfare regulations of the authors' institutions and Food and Drug Administration guidelines, including patient consent where appropriate. For more information, visit the *JACC: Cardiovascular Interventions* [author instructions page](#).

Manuscript received October 28, 2019; revised manuscript received February 26, 2020, accepted February 27, 2020.

**ABBREVIATIONS  
AND ACRONYMS****BMS** = bare-metal stent**DAPT** = dual-antiplatelet therapy**DCB** = drug-coated balloon**DES** = drug-eluting stent(s)**FFR** = fractional flow reserve**ISR** = in-stent restenosis**MB** = main branch**PCI** = percutaneous coronary intervention**SB** = side branch

stenoses while limiting the need for permanent or semipermanent implants to those lesions at high risk for acute vessel closure or unfavorable long-term results. Potentially, every PCI should aim at using the DCB-only strategy, which implies a similar approach for every lesion preparation. This requires an optimal angioplasty result, which may be assessed using angiography, physiology, or intravascular imaging, with drug delivery then performed with a DCB. Stent implantation may be performed for suboptimal results after lesion preparation (i.e., a dissection or unacceptable recoil primarily or as bailout after

DCB application if necessary).

Although their efficacy and safety have been proved for both in-stent restenosis (ISR) and native small-vessel disease, there are other emerging indications (e.g., bifurcation lesions, large-vessel disease, and high bleeding risk). Because of the recent publication of new randomized clinical trial data, the International DCB Consensus Group is updating its previous recommendations (1,2).

**LOCAL DRUG DELIVERY**

Coronary stents reduce restenosis and prevent acute vessel closure after balloon angioplasty (3). Until the introduction of dual-antiplatelet therapy (DAPT), their use was complicated by the frequent occurrence of acute stent thrombosis (4), but they later became the standard of care for obstructive coronary artery disease, delivering more favorable acute results and lower restenosis rates compared with angioplasty

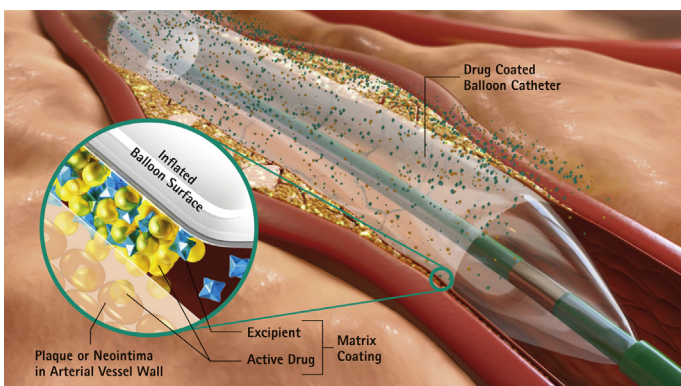
**HIGHLIGHTS**

- DES still have some limitations in certain clinical and anatomic conditions.
- DCBs are a novel therapeutic strategy for coronary artery disease.
- Besides ISR, new data show possible indications for native coronary artery disease.
- Future research will focus on alternative drug coatings and other possible indications.

alone (5). Drug-eluting stents (DES) were introduced to reduce ISR by a controlled, sustained release of antiproliferative drugs. However, a persistent concern even with second-generation DES has been the late occurrence of neoatherosclerosis and thrombotic events such as stent thrombosis (6). Therefore, DCBs have become attractive, as they fulfill the concept of “leaving nothing behind” without the elevated thrombotic risk seen with temporary implants such as bioresorbable scaffolds (7).

Negative vessel remodeling and neointimal hyperplasia both contribute to restenosis after angioplasty (8). These are slow processes that can be prevented by a sustained release of antiproliferative drugs for restenosis prevention (9). Initial experimental work demonstrated that non-stent-based approaches for local drug delivery would require rapid drug uptake by the tissue and drug persistence in the vessel wall to compensate for a short contact time (10-12). Although a variety of different coatings on balloon catheters were tested, concepts using taxane compounds such as paclitaxel and docetaxel were investigated (10), and a specific balloon coating using a contrast medium as an excipient resulted in a dose-dependent reduction of neointimal formation in a porcine coronary model (13). The combination of a highly lipophilic drug and a specific coating matrix was finally tested in a small first-in-human trial in coronary ISR, which showed a significantly lower incidence of restenosis (14). Of note, one of the important aspects of local paclitaxel therapy is the positive remodeling phenomenon, describing a late luminal increase after a successful DCB-only strategy (15,16).

Recently, sirolimus and its derivatives have been investigated for the use in DCBs. Limitations of “limus” substances are basically the poorer transfer rate compared with paclitaxel (17) and the necessary long persistence in tissue due to the reversible binding to the mammalian target of rapamycin receptor

**FIGURE 1 Drug-Coated Balloon Technique and Mechanism of Action**

Reproduced with permission from B. Braun.

**TABLE 1** Commercially Available DCBs

Drug and Device	Company	Additive	Substance Class	Dose ( $\mu\text{g}/\text{mm}^2$ )	Approval
<b>Paclitaxel</b>					
Agent	Boston Scientific	Acetyl tributyl citrate	Plasticizer	2	CE certified
Elutax SV	Aachen Resonance	None		2.2	CE certified
Danubio	Minvasys	n-Butyryl tri-n-hexyl citrate	Plasticizer	2.5	CE certified
SeQuent Please	B. Braun	Iopromide	X-ray contrast medium	3	CE certified
Pantera Lux	Biotronik	n-Butyryl tri-n-hexyl citrate	Plasticizer	3	CE certified
RESTORE	Cardionovum	Shellac	Varnish	3	CE certified
AngioSculptX	Spectranetics	Nordihydroguaiaretic acid	Antioxidant	3	CE certified
Chocolate Touch	QT Vascular	Undisclosed		3	CE certified
Dior II, BioStream	Eurocor Biosensors	Shellac	Varnish	3	
Essential	iVascular	Undisclosed		3	CE certified
IN.PACT (Admiral, Pacific, Falcon)	Medtronic Vascular	Urea	Endogenous metabolite	3.5	CE certified, FDA approved (Admiral)
<b>Sirolimus</b>					
Selution	Med Alliance	Biodegradable polymer	Microreservoirs		
Virtue	Caliber Therapeutics	Biodegradable polyester-based polymers	Submicrometer nanoparticles		
Magic Touch	Concept Medical		Phospholipids		CE certified
Sequent Please SCB	B. Braun		Crystalline sirolimus	4	CE certified

CE = Conformité Européenne; DCB = drug-coated balloon; FDA = U.S. Food and Drug Administration.

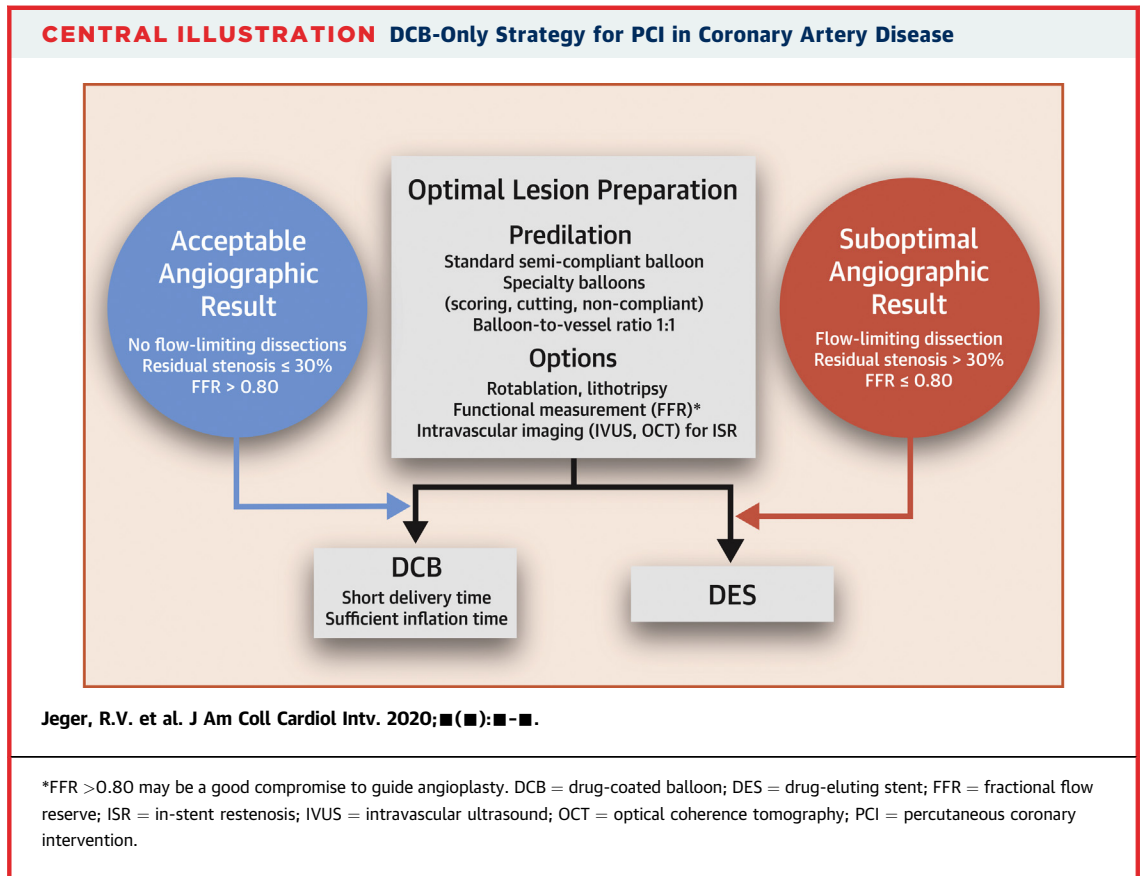
(18). Meanwhile, several concepts for local balloon-based administration of sirolimus or its analogues have been proposed (Table 1) (19–23). In preclinical models, a biological effect for a coating with zotarolimus instead of paclitaxel was demonstrated (20). The SABRE (Sirolimus Angioplasty Balloon for Coronary In-Stent Restenosis) trial reported the first clinical experience with sirolimus in a liquid formulation delivered by a porous balloon for coronary ISR (24). Another concept for balloon coating is the encapsulation of sirolimus in phospholipids (22). Unfortunately, only registry data have been presented for this approach. Although some of these sirolimus coatings on balloons showed a rapid decrease of tissue concentrations (19,22), a crystalline sirolimus coating with butylated hydroxytoluene as an excipient was associated with persistent vessel concentrations of up to 50% of the initial concentration at 1 month (23). In a clinical randomized trial using this formulation in DES ISR, in-segment late lumen loss after 6 months was similar between the paclitaxel- and the sirolimus-coated balloon groups, while clinical events did not differ between the groups up to 12 months (25).

Taken together, because the interaction among the doses, formulations, and release kinetics of the drugs used is important, there is no “class effect” of DCBs.

## TECHNICAL CONSIDERATIONS

**CHOICE OF DCB.** A wide variety of different DCBs are available for coronary use (Table 1). Paclitaxel is still the drug of choice, with a typical dose between 2 and 3.5  $\mu\text{g}/\text{mm}^2$  on the balloon surface. One of the critical factors enabling successful drug transfer is the coating formulation and the technique of the coating procedure, thus resulting in different pharmacokinetic profiles (26). Therefore, the interaction among drug doses, formulations, release kinetics, and lesions seems to be crucial for the vascular response after DCB therapy. As mentioned earlier, there is no evidence of a “class effect” among different platforms, as outlined in current guidelines (27).

**LESION PREPARATION.** In uncomplicated lesions, lesion preparation (Central Illustration) using a semi- or noncompliant balloon with a balloon-to-artery ratio of 1:1 is recommended (1,2). In anticipated difficult balloon delivery, vessel underfilling, or potential undersizing, it is reasonable to start with a smaller balloon and reassess vessel size after the use of vasodilators. In the case of expansion failure of a standard semicompliant balloon, high-pressure noncompliant balloons or cutting and scoring



balloons are recommended. Use of these specialty balloons may result in a more predictable and uniform pre-dilation result in comparison with standard balloons if any calcification is present in the vessel wall. In ISR, aggressive pre-dilation using high pressures may be recommended to tackle severe stent underexpansion. Optimal lesion preparation has been shown to reduce event rates after DCB interventions of ISR (28), with scoring balloons tending to improve results (29), which may apply to de novo lesions as well. Rarely, balloon angioplasty is not feasible or will not produce an adequate result. In such cases, any lesion preparatory adjunctive therapy, such as rotablation, laser or orbital atherectomy, lithotripsy, or prolonged dilation, may be considered (30,31). These ablative procedures can facilitate optimal balloon angioplasty and subsequent drug administration.

Once lesion preparation has been performed, an optimal balloon angioplasty result should be confirmed prior to DCB delivery, which consists of the following factors: 1) a fully inflated balloon of the correct size for the vessel; 2)  $\leq 30\%$  residual stenosis (32); 3) TIMI (Thrombolysis In Myocardial Infarction) flow grade 3; and 4) the absence of a flow-limiting

dissection. Specifically, angiography must exclude delayed contrast clearing from the vessel lumen, wall, and any dissection plane. According to pre-stent and pre-DAPT data, type A and B dissections have always been safe to leave after balloon angioplasty (33), whereas type C dissections are more open to debate, with some recent data suggesting good medium-term outcomes, exhibiting sealing of most of dissections without significant neointimal hyperplasia (16). Currently, any type C or greater dissection should be treated with stent implantation.

**FRACTIONAL FLOW RESERVE (FFR)-GUIDED ANGIOPLASTY.** In the setting of residual dissections and angiographically limited acute luminal gain after pre-dilation, the use of FFR has been advocated to better define the functional result, on the basis of the notion that an FFR value at the ischemic threshold is an appropriate value to leave untreated. Although historical data show that  $FFR > 0.90$  after balloon angioplasty is a good indicator of immediate functional improvement, with low restenosis rates in 2-year follow-up (34), more recent trials advise 0.85 (35) and even 0.75 after balloon angioplasty (36,37) as

**TABLE 2** Randomized Controlled Trials of DCBs in ISR

Study Name (Ref. #)	Comparators to PCB	n	Follow-Up Duration	Angiographic Follow-Up	p Value	MACE (%)	p Value	TLR (%)	p Value
<b>BMS ISR</b>									
PACOCATH ISR I and II (14)	POBA	108	6 months (angio) 12 months (clinical) 5 yrs (clinical)	LLL 0.03 ± 0.48 mm vs. 0.74 ± 0.86 mm	0.0002	4 vs. 31 27.8 vs. 59.3	0.01 0.009	0 vs. 23 9.3 vs. 38.9	0.02 0.004
PEPCAD II (97)	PES	131	6 months (angio) 12 months (clinical) 3 yrs (clinical)	LLL 0.17 ± 0.42 mm vs. 0.38 ± 0.61 mm	0.03	9 vs. 22 34.8 vs. 41.5	0.08	6 vs. 15	0.15
RIBS V (98)	EES	189	6-9 months (angio) 12 months (clinical) 3 yrs (clinical)	LLL 0.14 ± 0.5 mm vs. 0.04 ± 0.5 mm, binary restenosis 9.5% vs. 4.7%	0.14 0.22	8 vs. 6 12 vs. 10	0.60 0.64	6 vs. 1 8 vs. 2	0.09 0.04
SEDUCE (99)	EES	50	9 months (angio) 12 months (clinical)	LLL 0.28 mm vs. 0.07 mm, proportion uncovered struts (OCT) 1.4% vs. 3.1%	0.1 0.025			4.2 vs. 8	0.576
TIS (100)	EES	136	12 months	LLL 0.02 mm vs. 0.19 mm	0.0004	10.3 vs. 19.1	0.213	7.4 vs. 16.2 (TVR)	0.110
<b>DES ISR</b>									
PEPCAD-DES (101)	POBA	110	6 months (angio and clinical) 3 yrs	LLL 0.43 ± 0.61 mm vs. 1.03 ± 0.77 mm, restenosis 17.2% vs. 58.1%	<0.001 0.001	16.7 vs. 50.0 20.8 vs. 52.6	<0.001 0.001	15.3 vs. 36.8 19.4 vs. 36.8	0.005 0.046
PEPCAD CHINA ISR (102)	PES	220	9 months (angio) 12 months (clinical) 2 yrs (clinical)	LLL 0.46 ± 0.51 mm vs. 0.55 ± 0.61 mm	0.0005*	16.5 vs. 16 (TLF) 16.8 vs. 18.6 (TLF)	0.92 0.73	15.6 vs. 12.3 15.9 vs. 13.7	0.48 0.66
ISAR DESIRE III (103)	PES vs. POBA	402	6-8 months (angio) 12 months (clinical) 3 yrs (clinical)	Diameter stenosis 38% vs. 37.4%	0.007*	23.5 vs. 19.3 vs. 46.2 38.0 vs. 37.7 vs. 55.7	0.5 (PCB vs. PES) 0.91 (PCB vs. PES)	22.1 vs. 13.5 vs. 43.5 33.3 vs. 24.2 vs. 50.8	0.09 (PCB vs. PES) 0.11 (PCB vs. PES)
ISAR DESIRE IV (29)	Scoring and PCB	252	6-8 months (angio) 12 months (clinical)	LLL 0.31 ± 59 mm vs. 0.41 ± 0.74 mm	0.27	18.4 vs. 23.3	0.35	16.2 vs. 21.8	0.26
RIBS IV (104)	EES	309	6-9 months (angio) 12 months (clinical)	Binary restenosis 19% vs. 11%	0.06	18 vs. 10	0.04	16 vs. 8	0.035
RESTORE (105)	EES	172	9 months (angio) 12 months (clinical)	LLL 0.15 ± 0.49 mm vs. 0.19 ± 0.41 mm	0.54	7.0 vs. 4.7	0.51	5.8 vs. 1.2	0.10
FIM LIMUS DCB (25)	SCB	50	6 months (angio)	LLL 0.21 ± 0.54 mm vs. 0.17 ± 0.55 mm	0.794	16 vs. 12	>0.99	16 vs. 12	>0.99
<b>Mixed ISR</b>									
BIOLUX (106)	SES	229	6 months (angio) 12 months (clinical)	LLL 0.03 ± 0.40 mm vs. 0.20 ± 0.70 mm	0.40	16.9 vs. 14.2 (TLF)	0.65	12.5 vs. 10.1	0.82
DARE (107)	EES	278	6 months (angio) 12 months (clinical)	MLD 1.71 ± 0.51 mm vs. 1.74 ± 0.61 mm	<0.0001*	10.9 vs. 9.2	0.66	7.1 vs. 8.8 (TVR)	0.65

Only randomized controlled trials in ISR are included. \*Noninferiority.

angio = angiographic; BMS = bare metal stent; EES = everolimus-eluting stent; LLL = late lumen loss; MACE = major adverse clinical events; MLD = mean luminal diameter; ISR = in-stent restenosis; OCT = optical coherence tomography; PCB = paclitaxel-coated balloon; PES = paclitaxel-eluting stent; POBA = plain old balloon angioplasty; SCB = sirolimus-coated balloon; SES = sirolimus-eluting stent; TLF = target lesion failure; TLR = target lesion revascularization; TVR = target vessel revascularization.

optimal FFR cutoffs to predict future outcomes. Despite the absence of valid data on the ideal FFR threshold after plain balloon angioplasty, an FFR of 0.80 may be a good compromise to guide angioplasty (**Central Illustration**). This issue is one that should be further investigated.

**DCB DELIVERY.** First-generation DCBs were less deliverable than standard balloons with larger crossing profiles, whereas current-generation DCBs show improved deliverability. The passage of the

most recently used pre-dilation balloon may be used as a guide, while the presence of very distal lesions, extreme tortuosity, or excessive calcification should all increase the awareness of the possibility of DCB delivery failure. The use of a guiding catheter with good support, a guide extension, a buddy wire, or, with particular care, deep guide engagement are all options to aid balloon delivery. Care should be taken when handling a DCB, as some brands may shed drug and carrier when touched or after contact with liquid.

**TABLE 3** Randomized Controlled Trials of DCB Only in De Novo Lesions of Small Coronary Vessels

Study Name (Ref. #)	Comparators	n	Follow-Up Duration	Angiographic Follow-Up	p Value	MACE (%)	p Value	TLR (%)	p Value
PICCOLETO (58)	Dior PCB vs. TAXUS Liberté PES	57	6 months (angio) 9 months (clinical)	MLD $1.11 \pm 0.65$ mm vs. $1.94 \pm 0.72$ mm	0.0002	35.7 vs. 13.8	0.054	32.1 vs. 10.3	0.15
BELLO (59,66)	IN.PACT Falcon PCB vs. TAXUS Liberté PES	182	6 months (angio) 12 months (clinical) 3 yrs (clinical)	LLL $0.08 \pm 0.38$ mm vs. $0.29 \pm 0.44$ mm	0.001	10 vs. 16.3 14.4 vs. 30.4	0.21 0.015	4.4 vs. 7.6	0.37
RESTORE SVD (61)	Restore PCB vs. Resolute Integrity ZES	230	9-12 months (angio) 12 months (clinical)	LLL $0.26 \pm 0.42$ mm vs. $0.30 \pm 0.35$ mm, diameter stenosis $29.6 \pm 2.0\%$ vs. $24.1 \pm 2.0\%$	0.41, <0.001	9.6 vs. 9.6	1.0	4.4 vs. 2.6	0.72
BASKET-SMALL 2 (60)	Sequent Please PCB vs. TAXUS Element PES and Xience EES	758	6 months (angio)* 12 months (clinical)	LLL 0.13 mm (–0.14 to 0.57 mm) vs. 0.10 mm (–0.16 to 0.34 mm)	0.72	8 vs. 8	0.918, 0.0152†	3.4 vs. 4.5	0.438

Only randomized controlled trials in patients with lesions in native coronary vessels  $\leq 2.75$  or 3.0 mm are included. \*Only clinically indicated angiography. †Noninferiority. ZES = zotarolimus-eluting stent; other abbreviations as in Tables 1 and 2.

Each DCB brand will have specific instructions for use, and particular notice needs to be taken of the maximum transit time in the patient (i.e., before excessive drug loss has occurred) and the minimum inflation time for drug delivery (Central Illustration). Most manufacturers would not recommend reinsertion of the same DCB after delivery failure. The lesion that has undergone lesion preparation plus at least 2 mm proximally or distally should be covered with the DCB.

### ANGIOGRAPHIC INDICATIONS

**ISR.** ISR histologically is different from restenosis after angioplasty, because early after stent implantation increases the extent of neointimal hyperplasia (38). Although bare-metal stent (BMS) ISR is typically characterized by neointimal hyperplasia, DES ISR is typically characterized by neointimal hyperplasia with late neoatherosclerotic changes (39). In ISR populations (27,40,41), benefit from DCBs may be found in patients presenting with both BMS ISR and DES ISR (Table 2). However, patients with DES ISR represent a selected high-risk population with primary failure of local drug delivery by the stent (42,43), and the potential relative efficacy of DCBs versus DES according to the underlying tissue substrate (e.g., neointimal hyperplasia vs. neoatherosclerosis) may be different. On the basis of randomized trial data published in a large meta-analysis, DCBs are similarly effective as DES in the reduction of revascularization for BMS ISR, whereas they have somewhat lower efficacy in DES ISR (44). The necessity of a new permanent metal layer limits the attractiveness of repeat DES implantation compared with the use of a DCB. As a result, many

operators prefer the use of DCBs over DES in patients presenting with first ISR, reserving the use of a new DES layer for patients with subsequent recurrences after DCB treatment. The use of DCB instead of repeat DES implantation is particularly attractive in patients with multiple previous stent layers, those with relevant side branches emerging from the stent with ISR, and those who on clinical grounds may benefit from a shorter dual-antiplatelet regimen (40). Therefore, treatment of ISR has entered current guidelines on myocardial revascularization as a recommendation (Level of Evidence: IA) (27).

Lesion preparation of ISR lesions must carefully consider the underlying pathology, and guidance using intravascular imaging modalities can be extremely helpful and is highly recommended to detect “mechanical” causes of ISR failure and correct them accordingly (Central Illustration) (27,40). The requirements are essentially similar and independent of using a DCB or a DES as final treatment. However, the use of DCBs in conventionally undilatable lesions is limited. Rotablation (45), lithotripsy (46), and scoring or cutting balloons may be useful tools to improve stent expansion and luminal gain and to avoid slippage of pre-dilation balloons (47,48).

**DE NOVO LESIONS IN SMALL VESSELS.** The interventional treatment of coronary small-vessel disease, usually defined as lesions in vessels  $\leq 2.75$  or  $< 3.0$  mm, remains challenging. Although DES are as effective in small as in large vessels, the resulting late lumen loss occupies a higher percentage of the respective vessel diameter, leading to higher rates of ISR and clinical events (49). The clinical feasibility of the treatment of small-vessel disease with DCBs has initially been shown in several nonrandomized

**TABLE 4 DCB Only in De Novo Lesions of Large Coronary Vessels**

Study Name (Ref. #)	DCB	n	≥2.75-mm DCB (%)	≥3.0-mm DCB (%)	Bailout Stent (%)	MACE (%)	TLR (%)
DELUX (70)	Pantera Lux	105		23	22	9.4 (12 months)	3.1 (12 months) (TVR)
FALCON (69)	In.Pact Falcon	326	25		4.8	8.0 (12 months)	4.9 (12 months)
Venetsanos et al. (53)	SeQuent Please, In.Pact Falcon, Pantera Lux	985		6	8		3 (12 months)
Rosenberg et al. (54)	Sequent Please	731	21		6	5.6 (9 months)	2.3 (9 months)
Uskela et al. (68)	Sequent Please	463	79	60	12	6.1 (stable CAD, 12 months)	1.4 (stable CAD, 12 months)
Yu et al. (108)	Sequent Please	595	36		0.5	0 (10 months)	0 (10 months)
DEBUT (57)	Sequent Please vs. BMS (RCT)	103	76	64	2	1.9 (9 months)	0 (9 months)
PEPCAD-NSTEMI (62)	Sequent Please vs. BMS and DES (RCT)	104			17.4	3.8 (9 months)	1.0 (9 months)

Only studies including de novo lesion treatment in 100 patients or more and reporting device diameter are included.  
CAD = coronary artery disease; RCT = randomized controlled trial; other abbreviations as in Tables 1 and 2.

studies and registries (43,50-55), while subsequently several randomized clinical trials were performed comparing DCB and balloon angioplasty (56), BMS (57), and DES (58-62) (Table 3). In some of these trials, the lack of superior efficacy of DCBs versus angioplasty alone (56) was attributed to a very low event rate and of DCBs versus DES (58) to the types of DCBs used, in particular the excipient and rate of drug transfer, as well as an inadequate implantation technique and geographic mismatch (63). Accordingly, an earlier meta-analysis showed inferior results for DCBs compared with DES (64). However, recently published larger and adequately designed trials showed similar results for DCBs compared with the stents used as comparators. Specifically, the pivotal BASKET-SMALL 2 (Basel Stent Kosten Effektivitäts Trial Drug Eluting Balloons vs. Drug Eluting Stents in Small Vessel Interventions) study compared a paclitaxel-iopromide-coated DCB with second-generation DES regarding clinical endpoints and demonstrated noninferiority of the DCB to the second-generation DES in small-vessel disease (60). This result was corroborated by another randomized controlled trial (61). Meanwhile, the clinical efficacy of DCBs in small-vessel disease has been confirmed up to 3 years (53,65-67).

**DE NOVO LESIONS IN LARGE VESSELS.** There is growing evidence for the efficacy of the DCB-only strategy for the treatment of de novo lesions in large (≥3.0-mm) coronary arteries as well. In studies using the DCB-only approach, there variable proportions of large vessels treated (Table 4). On the basis of these reports, the treatment of de novo lesions in large coronary segments seems to be both safe and efficient, with low risk rates of clinical

events and acute vessel closure, which may be due to the lack of foreign material and its inherent thrombogenicity (53,54,57,62,68-70). However, randomized data for the comparison between DCBs and DES for this indication are still lacking.

**BIFURCATION LESIONS.** Coronary bifurcation lesions are encountered in up to 20% of PCI procedures (71). They present specific challenges in terms of both technical complexity and long-term clinical outcomes, the latter often compromised by suboptimal side branch (SB) results.

There are currently 2 DCB strategies for the treatment of bifurcation lesions: 1) DCB in SB and DES in main branch (MB); and 2) DCBs in both MB and SB. The updated European Society of Cardiology guidelines recommend MB stenting with provisional SB stenting as the default strategy for most bifurcation lesions (27). In this setting, the use of a DCB in the SB may be preferable to balloon angioplasty alone. Early studies looking into the use of a BMS in the MB in combination with a DCB in the SB demonstrated a low late lumen loss in the SB when treated alone with a DCB (72); recent observational studies focusing largely on a SB DCB combined with an MB DES strategy showed good SB results (73,74). In DCB-only PCI in de novo bifurcation lesions with SBs ≥2 mm, there were low rates of restenosis and target lesion revascularization (75,76), and this approach was superior for Medina class 0,1,1 lesions in a randomized trial compared with angioplasty alone (77,78).

A DCB-only intervention to the MB is often adequate and supported by the fact that ostial SB lesions may exhibit positive remodeling (79). Decision on balloon size across a bifurcation lesion can be difficult because of caliber change, but using the

distal MB reference diameter in such cases is reasonable when the distal-to-proximal MB ratio is in the range of 0.75:1 to 1:1 and the balloon and DCB adequately treat the more proximal vessel. If a strategy of treating both distal branches is chosen, the recommendation is to prepare both lesions sequentially, as for de novo DCB-only interventions. Subsequent DCB delivery is done in a similar fashion. Of note, DCB compared with DES use in bifurcations allows simplification of the procedure, and the majority of work can be performed in a sequential manner. Kissing balloon angioplasty is feasible in selected cases, although carina shift normally is caused by stent implantation and not by balloon angioplasty.

In summary, a DCB-only strategy for bifurcation lesions may be attempted, while a DES MB and DCB SB strategy may be chosen if there was a compromised result during the pre-dilatation stage.

### CLINICAL INDICATIONS

**DIABETES MELLITUS.** More than 25% of patients referred for coronary revascularization procedures have diabetes. Such patients are typically considered at high risk for cardiovascular events and exhibit poor outcomes post-PCI, with higher rates of ISR, stent thrombosis, myocardial infarction, and death (80,81) because of more complex, diffuse, and long lesions in smaller caliber vessels with reduced coronary vasodilator reserve (82). In these types of lesions, DCBs may be a favorable alternative to DES, as they are not subject to cracks and inhomogeneous distribution of coating, as observed in DES (83), potentially leading to platelet aggregation stent thrombosis, inflammation, and ISR (84). Although clinical experience, especially in countries with high diabetes prevalence and large registries (43,54), points to a very good response in vessels in patients with diabetes, the studies presented (85,86) predominantly used BMS as adjunctive or comparative treatment. More data and subgroup analyses await publication.

**HIGH BLEEDING RISK.** The volume of PCIs in elderly patients and those on oral anticoagulation because of atrial fibrillation are both predicted to increase, and these groups have 25% to 40% rates of bleeding complications in the first year post-procedure (87-89). Bleeding after PCI increases 1-year mortality considerably and causes other adverse outcomes such as nonfatal myocardial infarction, prolongs hospital stay, and should therefore be avoided (87,88).

DCBs offer advantages over stent implantation in patients at high bleeding risk. Although DAPT duration after PCI using DES has been shortened,

antithrombotic agents may be ceased in case of severe life-threatening bleeding earlier after DCB than after DES. The recommended duration of DAPT is 4 weeks after a DCB-only strategy in de novo vessels on the basis of expert opinion, with good results in recent clinical trials for patients in stable condition (57,60). There are preliminary data that PCI using DCBs may be performed only using single-antiplatelet therapy if bleeding risk is exceptionally high (e.g., because of recent bleeding or upcoming emergent surgery). In one large registry study, 4% of DCB-only PCIs were performed on single-antiplatelet therapy (68).

In a summary of randomized clinical trials and registries, there was no single case of an acute or a subacute thrombosis after a DCB-only strategy in more than 1,500 patients (89), whereas other investigators have reported an acute vessel thrombosis risk of only 0.2% after DCB-only PCI in comparison with stent implantation (53). Therefore, given the very low acute vessel thrombosis risk, DAPT duration after DCB might be shortened further in patients at high bleeding risk, and oral anticoagulation might be combined with a single antiplatelet agent in individual patients.

**ACUTE CORONARY SYNDROMES.** There are only limited data available for primary PCI (62,90-93). This patient subset brings particular reasons for the consideration of DCB (e.g., problems regarding correct vessel sizing). The technique is similar, but particular attention is paid to the avoidance of DCBs in the setting of obvious angiographic thrombus, which may inhibit drug delivery to the vessel wall. Restoring TIMI flow grade 3 and then staging interventions is also possible and may be particularly attractive for a DCB strategy (94). Just recently, the PEPCAD NSTEMI trial showed that a DCB-only strategy was noninferior to stent treatment in non-ST-segment elevation myocardial infarction (62), while similar results were found in the REVELATION (Drug-Coated Balloon Versus Drug-Eluting Stent in Acute Myocardial Infarction) trial for ST-segment elevation myocardial infarction (93).

### FUTURE PERSPECTIVES

In DES, mainly sirolimus and its derivatives are used in clinical practice. In contrast, the majority of currently available DCBs are coated with paclitaxel, while no real alternative to paclitaxel has hitherto been found for balloon-based applications, at least in preclinical studies (10). On the basis of its success in stent technology, sirolimus and its derivatives have also been investigated for DCB applications, and



several concepts for their use have been proposed (Table 1) (19-23). Because of the very limited data available, especially with regard to randomized controlled trials, it is currently not possible to finally assess the proper place of balloon coatings with substances other than paclitaxel. Given its potential to improve outcomes in many populations, it is of vital importance for this new technology that serious clinical research be carried out. This should be based on randomized studies that first investigate the biological efficacy and then the clinical safety and effectiveness.

### MORTALITY RISK WITH PACLITAXEL?

A recent meta-analysis raised the concern of increased mortality in patients with peripheral arterial disease and treated with paclitaxel stents and balloons (95). Although that study was subject to major statistical limitations, there has been no concern for the use of paclitaxel-coated balloons in the coronary vasculature on the basis of registry studies or randomized trials. A recent meta-analysis in patients treated with DCBs for coronary ISR (44) did not show increased mortality rates for paclitaxel-coated balloons, while another meta-analysis in patients treated with DCBs for coronary de novo stenosis did not show increased mortality rates up to 2 years but even lower mortality rates at 3 years for paclitaxel-coated balloons compared with DES (96).

### CONCLUSIONS

In the historical pre-DAPT era, balloon angioplasty of coronary artery lesions was abandoned because of unfavorable short- and long-term results. However, recent published randomized controlled trial data show that the DCB technique with optimal lesion preparation, functional testing, use of anti-proliferative drugs to inhibit intimal hyperplasia, and short-term DAPT has become a valid option for the treatment of coronary artery disease in many clinical situations. Although DCBs are an established therapeutic option for the treatment of ISR supported by guideline recommendations, a DCB-only approach in de novo lesions of coronary small-vessel disease is now a valid treatment alternative to DES if current recommendations regarding optimal balloon angioplasty and subsequent DCB delivery are adequately followed. In addition, there is growing evidence that other clinical situations, such as bifurcation lesions, PCI in large coronary vessels, or even complex coronary interventions, may benefit from a DCB-only approach. Randomized trials should be organized to determine if specific benefits might be achieved in patients with diabetes mellitus or at high bleeding risk.

**ADDRESS FOR CORRESPONDENCE:** Dr. Raban V. Jeger, Cardiology University Hospital Basel, University of Basel, Petersgraben 4, 4031 Basel, Switzerland. E-mail: [raban.jeger@usb.ch](mailto:raban.jeger@usb.ch).

### REFERENCES

- Kleber FX, Mathey DG, Rittger H, Scheller B, et al. Pathology of drug-eluting stents in humans: delayed healing and late thrombotic risk. *J Am Coll Cardiol* 2006; 48:193-202.
- Wykrzykowska JJ, Kraak RP, Hofma SH, et al. Bioresorbable scaffolds versus metallic stents in routine PCI. *N Engl J Med* 2017;376:2319-28.
- Holmes DR, Vlietstra RE, Smith HC, et al. Restenosis after percutaneous transluminal coronary angioplasty (PTCA): a report from the PTCA Registry of the National Heart, Lung, and Blood Institute. *Am J Cardiol* 1984;53:77C-81C.
- Gershlick AH. Treating atherosclerosis: local drug delivery from laboratory studies to clinical trials. *Atherosclerosis* 2002;160:259-71.
- Speck U, Scheller B, Rutsch W, Laule M, Stangl V. Local drug delivery—the early Berlin experience: single drug administration versus sustained release. *EuroIntervention* 2011;7 suppl K:K17-22.
- Herdeg C, Oberhoff M, Baumbach A, et al. Local paclitaxel delivery for the prevention of restenosis: biological effects and efficacy in vivo. *J Am Coll Cardiol* 2000;35:1969-76.
- Creel CJ, Lovich MA, Edelman ER. Arterial paclitaxel distribution and deposition. *Circ Res* 2000;86:879-84.
- Speck U, Scheller B, Abramjuk C, Grossmann S, Mahnkopf D, Simon O. Inhibition of restenosis in stented porcine coronary arteries: uptake of paclitaxel from angiographic contrast media. *Invest Radiol* 2004;39:182-6.
- Scheller B, Hehrlein C, Bocksch W, et al. Treatment of coronary in-stent restenosis with a paclitaxel-coated balloon catheter. *N Engl J Med* 2006;355:2113-24.
- Kleber FX, Schulz A, Waliszewski M, et al. Local paclitaxel induces late lumen enlargement in coronary arteries after balloon angioplasty. *Clin Res Cardiol* 2015;104:217-25.
- Cortese B, Silva Orrego P, Agostoni P, et al. Effect of drug-coated balloons in native coronary artery disease left with a dissection. *J Am Coll Cardiol Intv* 2015;8:2003-9.
- Gray WA, Granada JF. Drug-coated balloons for the prevention of vascular restenosis. *Circulation* 2010;121:2672-80.

18. Clever YP, Cremers B, Krauss B, et al. Paclitaxel and sirolimus differentially affect growth and motility of endothelial progenitor cells and coronary artery smooth muscle cells. *EuroIntervention* 2011;7 suppl K:K32-42.
19. Granada JF, Tellez A, Baumbach WR, et al. In vivo delivery and long-term tissue retention of nano-encapsulated sirolimus using a novel porous balloon angioplasty system. *EuroIntervention* 2016;12:740-7.
20. Cremers B, Toner JL, Schwartz LB, et al. Inhibition of neointimal hyperplasia with a novel zotarolimus coated balloon catheter. *Clin Res Cardiol* 2012;101:469-76.
21. Kolachalama VB, Pacetti SD, Franses JW, et al. Mechanisms of tissue uptake and retention in zotarolimus-coated balloon therapy. *Circulation* 2013;127:2047-55.
22. Lemos PA, Farooq V, Takimura CK, et al. Emerging technologies: polymer-free phospholipid encapsulated sirolimus nanocarriers for the controlled release of drug from a stent-plus-balloon or a stand-alone balloon catheter. *EuroIntervention* 2013;9:148-56.
23. Clever YP, Peters D, Calisse J, et al. Novel sirolimus-coated balloon catheter: in vivo evaluation in a porcine coronary model. *Circ Cardiovasc Interv* 2016;9:e003543.
24. Verheye S, Vrolix M, Kumsars I, et al. The SABRE trial (Sirolimus Angioplasty Balloon for Coronary In-Stent Restenosis): angiographic results and 1-year clinical outcomes. *J Am Coll Cardiol Intv* 2017;10:2029-37.
25. Ali RM, Abdul Kader MASK, Wan Ahmad WA, et al. Treatment of coronary drug-eluting stent restenosis by a sirolimus- or paclitaxel-coated balloon. *J Am Coll Cardiol Intv* 2019;12:558-66.
26. Speck U, Cremers B, Kelsch B, et al. Do pharmacokinetics explain persistent restenosis inhibition by a single dose of paclitaxel? *Circ Cardiovasc Interv* 2012;5:392-400.
27. Neumann FJ, Sousa-Uva M, Ahlsson A, et al. 2018 ESC/EACTS guidelines on myocardial revascularization. *Eur Heart J* 2019;40:87-165.
28. Tanaka A, Latib A, Jabbour RJ, et al. Impact of angiographic result after predilatation on outcome after drug-coated balloon treatment of in-stent coronary restenosis. *Am J Cardiol* 2016;118:1460-5.
29. Kufner S, Joner M, Schneider S, et al. Neointimal modification with scoring balloon and efficacy of drug-coated balloon therapy in patients with restenosis in drug-eluting coronary stents: a randomized controlled trial. *J Am Coll Cardiol Intv* 2017;10:1332-40.
30. Rissanen TT, Uskela S, Siljander A, et al. Percutaneous coronary intervention of complex calcified lesions with drug-coated balloon after rotational atherectomy. *J Interv Cardiol* 2017;30:139-46.
31. Ali ZA, McEntegart M, Hill JM, Spratt JC. Intravascular lithotripsy for treatment of stent underexpansion secondary to severe coronary calcification. *Eur Heart J* 2020;41:485-6.
32. Cox DA, Stone GW, Grines CL, et al. Outcomes of optimal or "stent-like" balloon angioplasty in acute myocardial infarction: the CADILLAC trial. *J Am Coll Cardiol* 2003;42:971-7.
33. Huber MS, Mooney JF, Madison J, Mooney MR. Use of a morphologic classification to predict clinical outcome after dissection from coronary angioplasty. *Am J Cardiol* 1991;68:467-71.
34. Bech GJ, Pijls NH, De Bruyne B, et al. Usefulness of fractional flow reserve to predict clinical outcome after balloon angioplasty. *Circulation* 1999;99:883-8.
35. Shin ES, Ann SH, Balbir Singh G, Lim KH, Kleber FX, Koo BK. Fractional flow reserve-guided paclitaxel-coated balloon treatment for de novo coronary lesions. *Catheter Cardiovasc Interv* 2016;88:193-200.
36. Her AY, Shin ES, Lee JM, et al. Paclitaxel-coated balloon treatment for functionally nonsignificant residual coronary lesions after balloon angioplasty. *Int J Cardiovasc Imaging* 2018;34:1339-47.
37. Poerner TC, Duderstadt C, Goebel B, Kretschmar D, Figulla HR, Otto S. Fractional flow reserve-guided coronary angioplasty using paclitaxel-coated balloons without stent implantation: feasibility, safety and 6-month results by angiography and optical coherence tomography. *Clin Res Cardiol* 2017;106:18-27.
38. Chieffo A, Foglieni C, Nodari RL, et al. Histopathology of clinical coronary restenosis in drug-eluting versus bare metal stents. *Am J Cardiol* 2009;104:1660-7.
39. Byrne RA, Joner M, Kastrati A. Stent thrombosis and restenosis: what have we learned and where are we going? The Andreas Grüntzig Lecture ESC 2014. *Eur Heart J* 2015;36:3320-31.
40. Alfonso F, Byrne RA, Rivero F, Kastrati A. Current treatment of in-stent restenosis. *J Am Coll Cardiol* 2014;63:2659-73.
41. Byrne RA, Joner M, Alfonso F, Kastrati A. Drug-coated balloon therapy in coronary and peripheral artery disease. *Nat Rev Cardiol* 2014;11:13-23.
42. Byrne RA, Cassese S, Windisch T, et al. Differential relative efficacy between drug-eluting stents in patients with bare metal and drug-eluting stent restenosis; evidence in support of drug resistance: insights from the ISAR-DESIRE and ISAR-DESIRE 2 trials. *EuroIntervention* 2013;9:797-802.
43. Wöhrle J, Zadura M, Möbius-Winkler S, et al. SeQuentPlease World Wide Registry: clinical results of SeQuent please paclitaxel-coated balloon angioplasty in a large-scale, prospective registry study. *J Am Coll Cardiol* 2012;60:1733-8.
44. Giacoppo D, Alfonso F, Xu B, et al. Paclitaxel-coated balloon angioplasty vs. drug-eluting stenting for the treatment of coronary in-stent restenosis: a comprehensive, collaborative, individual patient data meta-analysis of 10 randomized clinical trials (DAEDALUS study). *Eur Heart J*. In press.
45. Alfonso F, Sandoval J, Nolte C. Calcified in-stent restenosis: a rare cause of dilation failure requiring rotational atherectomy. *Circ Cardiovasc Interv* 2012;5:e1-2.
46. Alfonso F, Bastante T, Antuña P, et al. Coronary lithoplasty for the treatment of undilatable calcified de novo and in-stent restenosis lesions. *J Am Coll Cardiol Intv* 2019;12:497-9.
47. Alfonso F, Pérez-Vizcayno MJ, Gómez-Recio M, et al. Implications of the "watermelon seeding" phenomenon during coronary interventions for in-stent restenosis. *Catheter Cardiovasc Interv* 2005;66:521-7.
48. Albiero R, Silber S, Di Mario C, et al. Cutting balloon versus conventional balloon angioplasty for the treatment of in-stent restenosis: results of the restenosis cutting balloon evaluation trial (RESCUT). *J Am Coll Cardiol* 2004;43:943-9.
49. Biondi-Zoccai G, Moretti C, Abbate A, Sheiban I. Percutaneous coronary intervention for small vessel coronary artery disease. *Cardiovasc Revasc Med* 2010;11:189-98.
50. Unverdorben M, Kleber F, Heuer H, et al. Treatment of small coronary arteries with a paclitaxel-coated balloon catheter. *Clin Res Cardiol* 2010;99:165-74.
51. Waksman R, Serra A, Loh JP, et al. Drug-coated balloons for de novo coronary lesions: results from the Valentines II trial. *EuroIntervention* 2013;9:613-9.
52. Vaquerizo B, Miranda-Guardiola F, Fernández E, et al. Treatment of small vessel disease with the paclitaxel drug-eluting balloon: 6-month angiographic and 1-year clinical outcomes of the Spanish Multicenter Registry. *J Interv Cardiol* 2015;28:430-8.
53. Venetsanos D, Lawesson SS, Panayi G, et al. Long-term efficacy of drug coated balloons compared with new generation drug-eluting stents for the treatment of de novo coronary artery lesions. *Catheter Cardiovasc Interv* 2018;92:E317-26.
54. Rosenberg M, Waliszewski M, Chin K, et al. Prospective, large-scale multicenter trial for the use of drug-coated balloons in coronary lesions: the DCB-Only All-Comers Registry. *Catheter Cardiovasc Interv* 2019;93:181-8.
55. Sim HW, Ananthakrishna R, Chan SP, et al. Treatment of very small de novo coronary artery disease with 2.0 mm drug-coated balloons showed 1-year clinical outcome comparable with 2.0 mm drug-eluting stents. *J Invasive Cardiol* 2018;30:256-61.
56. Funatsu A, Nakamura S, Inoue N, et al. A multicenter randomized comparison of paclitaxel-coated balloon with plain balloon angioplasty in patients with small vessel disease. *Clin Res Cardiol* 2017;106:824-32.
57. Rissanen TT, Uskela S, Eränen J, et al. Drug-coated balloon for treatment of de-novo coronary artery lesions in patients with high bleeding risk (DEBUT): a single-blind, randomised, non-inferiority trial. *Lancet* 2019;394:230-9.
58. Cortese B, Micheli A, Picchi A, et al. Paclitaxel-coated balloon versus drug-eluting stent during PCI of small coronary vessels, a prospective randomised clinical trial. The PICCOLETO study. *Heart* 2010;96:1291-6.
59. Latib A, Colombo A, Castriota F, et al. A randomized multicenter study comparing a

paclitaxel drug-eluting balloon with a paclitaxel-eluting stent in small coronary vessels: the BELLO (Balloon Elution and Late Loss Optimization) study. *J Am Coll Cardiol* 2012;60:2473-80.

**60.** Jeger RV, Farah A, Ohlow MA, et al. Drug-coated balloons for small coronary artery disease (BASKET-SMALL 2): an open-label randomised non-inferiority trial. *Lancet* 2018;392:849-56.

**61.** Tang Y, Qiao S, Su X, et al. Drug-coated balloon versus drug-eluting stent for small-vessel disease: the RESTORE SVD China randomized trial. *J Am Coll Cardiol Interv* 2018;11:2381-92.

**62.** Scheller B, Ohlow MA, Ewen S, et al. Randomized comparison of bare metal or drug-eluting stent versus drug coated balloon in non-ST-elevation myocardial infarction—PEPCAD NSTEMI. *EuroIntervention*. In press.

**63.** Cortese B. The PICCOLETO study and beyond. *EuroIntervention* 2011;7:K53-6.

**64.** Siontis GC, Piccolo R, Praz F, et al. Percutaneous coronary interventions for the treatment of stenoses in small coronary arteries: a network meta-analysis. *J Am Coll Cardiol Interv* 2016;9:1324-34.

**65.** Naganuma T, Latib A, Sgueglia GA, et al. A 2-year follow-up of a randomized multicenter study comparing a paclitaxel drug-eluting balloon with a paclitaxel-eluting stent in small coronary vessels the BELLO study. *Int J Cardiol* 2015;184:17-21.

**66.** Latib A, Ruparelia N, Menozzi A, et al. 3-Year follow-up of the Balloon Elution and Late Loss Optimization Study (BELLO). *J Am Coll Cardiol Interv* 2015;8:1132-4.

**67.** Unverdorben M, Kleber FX, Heuer H, et al. Treatment of small coronary arteries with a paclitaxel-coated balloon catheter in the PEPCAD I study: are lesions clinically stable from 12 to 36 months? *EuroIntervention* 2013;9:620-8.

**68.** Uskela S, Kärkkäinen JM, Eränen J, et al. Percutaneous coronary intervention with drug-coated balloon-only strategy in stable coronary artery disease and in acute coronary syndromes: an all-comers registry study. *Catheter Cardiovasc Interv* 2019;93:893-900.

**69.** Widder JD, Cortese B, Levesque S, et al. Coronary artery treatment with an urea-based paclitaxel-coated balloon: the European wide Falcon all comers DCB Registry (FALCON-Registry). *EuroIntervention* 2018;15:e382-8.

**70.** Toelg R, Merkely B, Erglis A, et al. Coronary artery treatment with paclitaxel-coated balloon using a BTHC excipient: clinical results of the international real-world DELUX registry. *EuroIntervention* 2014;10:591-9.

**71.** Sawaya FJ, Lefèvre T, Chevalier B, et al. Contemporary approach to coronary bifurcation lesion treatment. *J Am Coll Cardiol Interv* 2016;9:1861-78.

**72.** Mathey DG, Wendig I, Boxberger M, Bonaventura K, Kleber FX. Treatment of bifurcation lesions with a drug-eluting balloon: the PEPCAD V (Paclitaxel Eluting PTCA Balloon in Coronary Artery Disease) trial. *EuroIntervention* 2011;7 suppl K:K61-5.

**73.** Worthley S, Hendriks R, Worthley M, et al. Paclitaxel-eluting balloon and everolimus-eluting

stent for provisional stenting of coronary bifurcations: 12-month results of the multicenter BIOLUX-I study. *Cardiovasc Revasc Med* 2015;16:413-7.

**74.** Berland J, Lefèvre T, Brenot P, et al. DANUBIO—a new drug-eluting balloon for the treatment of side branches in bifurcation lesions: six-month angiographic follow-up results of the DEBSIDE trial. *EuroIntervention* 2015;11:868-76.

**75.** Schulz A, Hauschild T, Kleber FX. Treatment of coronary de novo bifurcation lesions with DCB only strategy. *Clin Res Cardiol* 2014;103:451-6.

**76.** Bruch L, Zadura M, Waliszewski M, et al. Results from the International Drug Coated Balloon Registry for the Treatment of Bifurcations. Can a bifurcation be treated without stents? *J Interv Cardiol* 2016;29:348-56.

**77.** Kleber FX, Rittger H, Ludwig J, et al. Drug eluting balloons as stand alone procedure for coronary bifurcational lesions: results of the randomized multicenter PEPCAD-BIF trial. *Clin Res Cardiol* 2016;105:613-21.

**78.** Lassen JF, Burzotta F, Banning AP, et al. Percutaneous coronary intervention for the left main stem and other bifurcation lesions: 12th consensus document from the European Bifurcation Club. *EuroIntervention* 2018;13:1540-53.

**79.** Her AY, Ann SH, Singh GB, et al. Serial morphological changes of side-branch ostium after paclitaxel-coated balloon treatment of de novo coronary lesions of main vessels. *Yonsei Med J* 2016;57:606-13.

**80.** Mehran R, Dangas GD, Kobayashi Y, Lansky AJ, Mintz GS, Aymong ED, et al. Short- and long-term results after multivessel stenting in diabetic patients. *J Am Coll Cardiol* 2004;43:1348-54.

**81.** Berry C, Tardif JC, Bourassa MG. Coronary heart disease in patients with diabetes: part II: recent advances in coronary revascularization. *J Am Coll Cardiol* 2007;49:643-56.

**82.** Lee CW, Park DW, Lee BK, et al. Predictors of restenosis after placement of drug-eluting stents in one or more coronary arteries. *Am J Cardiol* 2006;97:506-11.

**83.** Denardo SJ, Carpinone PL, Vock DM, et al. Detailed analysis of polymer response to delivery balloon expansion of drug-eluting stents versus bare metal stents. *EuroIntervention* 2013;9:389-97.

**84.** Kukulka K, Klopotoski M, Kunicki PK, et al. Platelet aggregation and risk of stent thrombosis or bleeding in interventional treated diabetic patients with acute coronary syndrome. *BMC Cardiovasc Disord* 2016;16:252.

**85.** Ali RM, Degenhardt R, Zambahari R, et al. Paclitaxel-eluting balloon angioplasty and cobalt-chromium stents versus conventional angioplasty and paclitaxel-eluting stents in the treatment of native coronary artery stenoses in patients with diabetes mellitus. *EuroIntervention* 2011;7 suppl K:K83-92.

**86.** Mieres J, Fernandez-Pereira C, Risau G, et al. One-year outcome of patients with diabetes mellitus after percutaneous coronary intervention with three different revascularization strategies:

results from the Diabetic Argentina Registry (DEAR). *Cardiovasc Revasc Med* 2012;13:265-71.

**87.** Li SX, Chaudry HI, Lee J, et al. Patterns of in-hospital mortality and bleeding complications following PCI for very elderly patients: insights from the Dartmouth Dynamic Registry. *J Geriatr Cardiol* 2018;15:131-6.

**88.** Palmerini T, Della Riva D, Benedetto U, et al. Three, six, or twelve months of dual antiplatelet therapy after DES implantation in patients with or without acute coronary syndromes: an individual patient data pairwise and network meta-analysis of six randomized trials and 11 473 patients. *Eur Heart J* 2017;38:1034-43.

**89.** Kleber F, Scheller B, Ong P, et al. Duration of dual antiplatelet therapy after drug-coated balloon implantation. *J Am Coll Cardiol* 2018;72 13 suppl:B309-10.

**90.** Vos NS, Dirksen MT, Vink MA, et al. Safety and Feasibility of a Paclitaxel-Eluting Balloon Angioplasty in Primary Percutaneous Coronary Intervention in Amsterdam (PAPPA): one-year clinical outcome of a pilot study. *EuroIntervention* 2014;10:584-90.

**91.** Ho HH, Tan J, Ooi YW, et al. Preliminary experience with drug-coated balloon angioplasty in primary percutaneous coronary intervention. *World J Cardiol* 2015;7:311-4.

**92.** Nijhoff F, Agostoni P, Belkacemi A, et al. Primary percutaneous coronary intervention by drug-eluting balloon angioplasty: the nonrandomized fourth arm of the DEB-AMI (Drug-Eluting Balloon in ST-Segment Elevation Myocardial Infarction) trial. *Catheter Cardiovasc Interv* 2015;86 suppl 1: S34-44.

**93.** Vos NS, Fagel ND, Amoroso G, et al. Paclitaxel-coated balloon angioplasty versus drug-eluting stent in acute myocardial infarction: the REVELATION randomized trial. *J Am Coll Cardiol Interv* 2019;12:1691-9.

**94.** Carrick D, Oldroyd KG, McEntegart M, et al. A randomized trial of deferred stenting versus immediate stenting to prevent no- or slow-reflow in acute ST-segment elevation myocardial infarction (DEFER-STEMI). *J Am Coll Cardiol* 2014;63:2088-98.

**95.** Katsanos K, Spiliopoulos S, Kitrou P, Krokidis M, Karnabatidis D. Risk of death following application of paclitaxel-coated balloons and stents in the femoropopliteal artery of the leg: a systematic review and meta-analysis of randomized controlled trials. *J Am Heart Assoc* 2018;7: e011245.

**96.** Scheller B, Vukadinovic D, Jeger R, et al. Survival after coronary revascularization with paclitaxel-coated balloons. *J Am Coll Cardiol* 2020;75:1017-28.

**97.** Unverdorben M, Vallbracht C, Cremers B, et al. Paclitaxel-coated balloon catheter versus paclitaxel-coated stent for the treatment of coronary in-stent restenosis. *Circulation* 2009;119:2986-94.

**98.** Alfonso F, Pérez-Vizcayno MJ, Cárdenas A, et al. A randomized comparison of drug-eluting balloon versus everolimus-eluting stent in patients with bare-metal stent-in-stent restenosis: the RIBS V clinical trial (Restenosis Intra-Stent of

- Bare Metal Stents: Paclitaxel-Eluting Balloon vs. Everolimus-Eluting Stent). *J Am Coll Cardiol* 2014;63:1378-86.
- 99.** Adriaenssens T, Dens J, Ughi G, et al. Optical coherence tomography study of healing characteristics of paclitaxel-eluting balloons vs. everolimus-eluting stents for in-stent restenosis: the SEDUCE (Safety and Efficacy of a Drug Eluting Balloon in Coronary Artery Restenosis) randomised clinical trial. *EuroIntervention* 2014;10:439-48.
- 100.** Pleva L, Kukla P, Kusnierova P, Zapletalova J, Hlinomaz O. Comparison of the efficacy of paclitaxel-eluting balloon catheters and everolimus-eluting stents in the treatment of coronary in-stent restenosis: the Treatment of In-Stent Restenosis Study. *Circ Cardiovasc Interv* 2016;9:e003316.
- 101.** Rittger H, Brachmann J, Sinha AM, et al. A randomized, multicenter, single-blinded trial comparing paclitaxel-coated balloon angioplasty with plain balloon angioplasty in drug-eluting stent restenosis: the PEPCAD-DES study. *J Am Coll Cardiol* 2012;59:1377-82.
- 102.** Xu B, Gao R, Wang J, et al. A prospective, multicenter, randomized trial of paclitaxel-coated balloon versus paclitaxel-eluting stent for the treatment of drug-eluting stent in-stent restenosis: results from the PEPCAD China ISR trial. *J Am Coll Cardiol Intv* 2014;7:204-11.
- 103.** Byrne RA, Neumann FJ, Mehilli J, et al. Paclitaxel-eluting balloons, paclitaxel-eluting stents, and balloon angioplasty in patients with restenosis after implantation of a drug-eluting stent (ISAR-DESIRE 3): a randomised, open-label trial. *Lancet* 2013;381:461-7.
- 104.** Alfonso F, Pérez-Vizcayno MJ, Cárdenas A, et al. A prospective randomized trial of drug-eluting balloons versus everolimus-eluting stents in patients with in-stent restenosis of drug-eluting stents: the RIBS IV randomized clinical trial. *J Am Coll Cardiol* 2015;66:23-33.
- 105.** Wong YTA, Kang DY, Lee JB, et al. Comparison of drug-eluting stents and drug-coated balloon for the treatment of drug-eluting coronary stent restenosis: a randomized RESTORE trial. *Am Heart J* 2018;197:35-42.
- 106.** Jensen CJ, Richardt G, Tölg R, et al. Angiographic and clinical performance of a paclitaxel-coated balloon compared to a second-generation sirolimus-eluting stent in patients with in-stent restenosis: the BIOLUX randomised controlled trial. *EuroIntervention* 2018;14:1096-103.
- 107.** Baan J, Claessen BE, Dijk KB, et al. A randomized comparison of paclitaxel-eluting balloon versus everolimus-eluting stent for the treatment of any in-stent restenosis: the DARE trial. *J Am Coll Cardiol Intv* 2018;11:275-83.
- 108.** Yu X, Ji F, Xu F, et al. Treatment of large de novo coronary lesions with paclitaxel-coated balloon only: results from a Chinese institute. *Clin Res Cardiol* 2019;108:234-43.

---

**KEY WORDS** consensus statement, coronary artery disease, drug-coated balloon